

Allium™ TPS—A New Prostatic Stent for the Treatment of Patients with Benign Prostatic Obstruction: The First Report

Guner Yildiz, MD,^{1,*} Zaher Bahouth, MD,^{2,*} Sarel Halachmi, MD,² Gil Meyer, MD,²
Ofer Nativ, MD,² and Boaz Moskovitz, MD²

Abstract

Introduction: Several prostatic stents were developed in the last three decades, none of which were able to provide a real alternative in patients unfit or unwilling to undergo classical prostatic surgeries. In this study, we report the results of the use of a newly developed prostatic stent—the Allium™ Triangular Prostatic Stent (TPS).

Patients and Methods: The Allium TPS is a highly flexible, nitinol-built polymer-covered stent, which prevents tissue ingrowth and reduces encrustations. Between 2008 and 2014, at two centers (Israel and Turkey), the stent was inserted under local or regional anesthesia in 51 patients with benign prostatic obstruction (BPO) who are unwilling or unfit for surgery. Patients were followed for 12 months from surgery. The primary outcome was symptom improvement as measured by the international prostate symptom score (IPSS) and improvement in peak urinary flow.

Results: Stent insertion was successful in all patients. The mean IPSS decreased from 26.4 to 7.7 on the last follow-up. The mean peak flow increased from 5.5 mL/second before stent insertion to 16.0 mL/second 1 year thereafter. The main adverse effect was transient pain in nine patients. No stent migration or obstruction was seen. Patients reported satisfaction and improvement in quality of life.

Conclusion: Our short-term results show that Allium TPS is safe and effective for the treatment of patients with BPO.

Introduction

PROSTATIC STENT WAS first described by Fabian in 1980 as an alternative for chronic indwelling catheter and was named partial catheter.¹ Since then, several prostatic stents were developed and assessed for the treatment of benign prostatic obstruction (BPO) as an alternative for surgical treatment.^{2–4} Prostatic stents can be temporary, thus not enabling epithelialization, or permanent and as such should be biocompatible and allowing epithelialization.⁵

Regarding efficacy, all clinically studied prostatic stents showed some degree of symptoms (international prostate symptom score [IPSS]) and flow (maximal urinary flow [Qmax]) improvement.^{2,3,6–9} However, several stents showed high short- and long-term failure rates of as much as 46% in 3 months.⁹

The stent design can significantly affect its safety and efficacy. This fact has been shown in a randomized controlled study of blind prostatic stents.¹⁰

The available stents in use nowadays have a high failure rate and significant side effects, and as such, the latest European Association of Urology (EAU) guidelines state that prostatic stents have a limited role in the treatment of moderate-to-severe low urinary tract symptoms (LUTS).

In our study, we are reporting the efficacy and safety of a newly designed prostatic stent called Allium™ Triangular Prostatic Stent (Allium™ TPS; by Allium Medical, Caesarea, Israel).

Patients and Methods

Stent design

Allium TPS is a coiled, superelastic highly flexible stent built of nitinol and fully covered with a copolymer, which prevents tissue ingrowth. It also reduces encrustations, stone formation, and calcifications. The stent (shown in Fig. 1) is designed in a triangular shape, which, compared with circular stents, allows for less tissue to be pushed aside, causing less

¹Department of Urology, Dr. Suat Seren Chest Diseases and Surgery Teaching and Research Hospital, Izmir, Turkey.

²Department of Urology, Faculty of Medicine, Bnai-Zion Medical Center, Technion Institute of Technology, Haifa, Israel.

*These authors contributed equally to this work.



FIG. 1. Allium™ triangular prostatic stent (TPS) and Tiemman-like delivery system.

irritative symptoms. It is built of a body of eight different lengths ranging from 30 to 65 mm with a large caliber (45F); attached to the body with a trans-sphincteric wire is an anchor (Fig. 1), which reduces the chance of stent migration. Once inserted into the urethra with the aid of its special inserter, the stent is released to allow its self-expansion.

Stent insertion

Patients received prophylaxis antibiotics before surgery with vancomycin and third-generation cephalosporin. Stent insertion can be done under local or regional anesthesia with minimal patient discomfort using a specially designed delivery system (Fig. 2). First, a 12F measuring catheter is inserted and its balloon inflated with 15 mL saline. Then, a 15F to 17F cystoscope is inserted beside the catheter and advanced to the bladder neck. The balloon is then pulled to the bladder neck and the cystoscope withdrawn while counting the marks on the measuring catheter between the bladder neck and the verumontanum. This measure gives the length of the prostatic urethra and its appropriate Allium TPS length (30–65 mm, with 5 mm difference between each). The cystoscope and the measuring catheter are then removed and the delivery system, which includes the stent, is inserted (like a urethral catheter) and its balloon inflated with 15 mL saline (Fig. 2). While keeping the balloon at the bladder neck with gentle traction, the trigger on the delivery system should be pulled 6 to 10 times until the stent is totally deployed (Fig. 2). The balloon is then deflated and the delivery system removed. Another important feature of the Allium TPS stent is the unraveling feature, which ensures a safe, easy, and nontraumatic removal (Fig. 3).

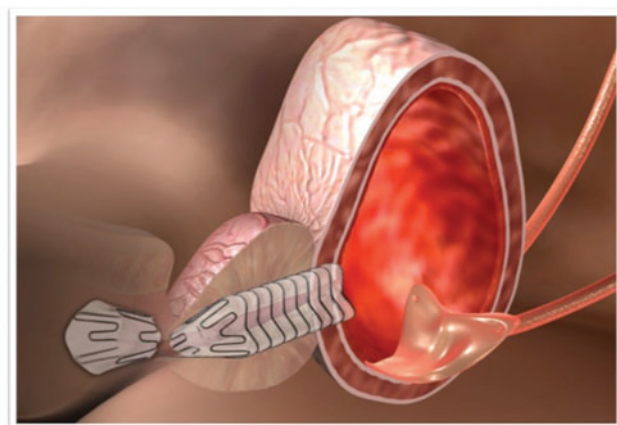


FIG. 2. Illustration of indwelling Allium TPS.

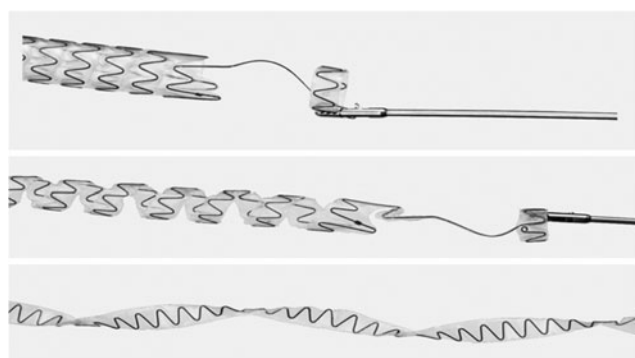


FIG. 3. Unraveling feature of Allium TPS.

Patients

Between 2008 and 2014, 51 Allium TPSs were inserted in 51 patients with clinically diagnosed severe BPO, who failed medical treatment, and were not willing or unfit (because of high risk for anesthetic complications) to undergo classical prostatic surgery. BPO was diagnosed based on the clinical diagnosis score (IPSS >20) and decreased Qmax (<10 mL/second). All procedures were performed in the following urology departments: Bnai-Zion Medical Center, Haifa, Israel and Dr. Suat Seren Chest Diseases and Surgery Teaching and Research Hospital, Izmir, Turkey. All patients received a detailed explanation of the procedure and its sequelae. All patients signed an informed consent form and each institutional review board approved the study. Exclusion criteria included age younger than 18 years, acute urinary tract infection, patients with penile or artificial sphincter implants, cystolithiasis, atonic bladder, non-BPO-related LUTS, and patients with large prostate volume (>100 cc).

Patients were discharged on postoperative day 1. Follow-up data were obtained on postoperative day 1 and 3, 6, and 12 months following surgery. Follow-up data included peak urinary flow, postvoiding residual (PVR), and patient-assessed IPSS. In addition, patients were asked about adverse events related to stent insertion.

Statistical analyses

Continuous variables were summarized with a mean standard deviation and median. Categorical variables were analyzed by a count and percentage. Peak flow, IPSS, and PVR were all analyzed with repeated-measures ANOVA (SAS PROC MIXED), where each was modeled as a function

TABLE 1. PATIENTS' BASELINE CHARACTERISTICS

Parameter, units	Mean (median, range)
Age, years	72.8 (73, 59–93)
ASA score	3 ^a
Prostate volume ^b , cc	38 (33, 11–75)
Peak urinary flow, mL/second	5.5 (5, 3.8–8.0)
IPSS	26.4 (27, 22–29)
PVR, cc	58.8 (62.5, 10–100)

^aAll patients had an ASA score of 3, except one (ASA=4).

^bMeasured by abdominal ultrasonography.

ASA, American Society of Anesthesiologists; IPSS, international prostate symptom score; PVR, postvoiding residual.

TABLE 2. ALLIUM TRIANGULAR PROSTATIC STENT USED

Stent length (mm)	No. (%)
30	17 (33.3)
35	9 (17.7)
40	14 (27.4)
45	8 (15.7)
50	2 (3.9)
55	1 (2)

of visit. Least squares (LS) mean (model-estimated means) differences between the visits were estimated from the models and are presented with respective levels of significance (only for the baseline to 12-month visit, others are not shown). All statistical tests were two-sided and tested at a 5% level of significance. Nominal *p*-values are presented. Statistical analyses were performed using SAS V9.3 (SAS Institute, Cary, NC).

Results

Patients' baseline characteristics are summarized in Table 1. Patients' mean age was 72.8 ± 7.4 (Median = 73) years and all, except one, had an American Society of Anesthesiologists (ASA) score of 3. Mean prostate volume, as measured by abdominal ultrasonography, was 38 ± 14.6 cc (Median = 33). All patients had severe symptoms with IPSS of 22 or more. All patients had abnormal peak urinary flow with a mean of 5.5 ± 1.4 mL/second (Median = 5) and a range of 3.8 to 8.0 mL/second. Mean PVR was 58.8 ± 37 cc (Median = 62.5).

Stent insertion was done in all 51 patients under local or regional anesthesia with no intraoperative complications. Six different stent lengths were used as shown in Table 2.

Immediately following stent insertion, all patients had statistically significant improvement in peak urinary flow. On the last available follow-up (12 months following surgery), all patients had significantly higher peak flow and significant improvement in IPSS. The mean IPSS significantly decreased from 26.4 to 7.7 on the last follow-up (Table 3). The mean peak flow significantly increased from 5.5 mL/second before stent insertion to 16.0 mL/second 1 year following thereafter. Most patients reported significant improvement in quality of life when asked to compare current symptoms with preoperative symptoms. Data are summarized in Table 3.

The stent was tolerated in all patients, with few adverse effects. The main complications are summarized in Table 4. Most adverse events were mild (Clavien–Dindo grade I or II). However, two patients had Clavien–Dindo grade III complications and needed surgery for stent removal. The 12-month failure rate was 3.9% (two patients: the first patient

TABLE 4. COMPLICATIONS FOLLOWING STENT INSERTION

Complication	No. (%)
Pain	9 (18)
Hematuria ^a	1 (1.9)
Infection ^a	5 (9.8)
Stent migration	0
Stent occlusion	0

^aTwo stents were removed: one due to hematuria (after 2 months) and the other due to chronic infection (after 1 month).

underwent stent removal 1 month from insertion due to chronic infection; the second patient underwent stent removal 2 months following insertion due to recurrent gross hematuria). The main adverse effect was pain in nine patients (18%), which resolved in all patients in 1 to 5 days after stent insertion. Another adverse effect was infection, seen in five patients (9.8%), which resolved in all but one patient after an antibiotics course. None of the patients reported stent-induced incontinence. No stent migration or occlusions were seen in any of the patients.

Discussion

Prostatic stent is a three-decade-old idea, but since its introduction, several improvements have been implemented. The stents that are in clinical use nowadays have limited role mainly due to high failure rates.^{11,12}

In a systematic review of 990 patients who underwent UroLume[®] stent insertion, Armitage et al. reported a 16% failure rate in the first year (only 61% of the patients were evaluable at that point).¹¹ In another systematic review of Memokath[®] thermo-expanding metallic stent, failure rates of as much as 48% were reported.¹²

The main reasons of failure after Memokath or UroLume insertions were incorrect stent placement, stent migration, encrustations, urinary retention (stent occlusion), and incontinence.^{11,12} Allium TPS was designed to overcome these limitations. The delivery system makes stent placement easy and safe, minimizing the risk of stent misplacement. The anchoring part, which is placed in the urethra, minimizes the risk of stent migration. The Allium TPS is coated with a specifically designed copolymer that prevents tissue ingrowth and encrustations. None of the patients had encrustations. Moreover, none of the stents were occluded. None of our patients had urinary incontinence following Allium TPS insertion. The reason for this finding is the trans-sphincteric wire, which does not compress the sphincter.

Markovic and coworkers were the first to report the use of Allium stents, including TPS, in preliminary studies of safety.¹³

TABLE 3. BASELINE AND POSTOPERATIVE DATA OF MEAN AND LEVEL OF SIGNIFICANCE

Parameter	Baseline	POD1	3 months	6 months	12 months	p
Peak flow, mL/second	5.5 ± 1.4	15.3 ± 1.8	15.9 ± 1.5	15.9 ± 1.4	16.0 ± 1.6	<0.0001
IPSS	26.4 ± 1.8	NR	8 ± 2.0	7.8 ± 1.9	7.7 ± 1.9	<0.0001
PVR, cc	58.7 ± 37.0	66.3 ± 17.5	NA	NA	NA	0.66

p-Value is the level of significance of the LS mean difference between baseline and 12 months from the repeated-measures ANOVA models.

ANOVA, analysis of variance; LS, least squares; NA, not available; NR, not relevant.

However, no data were published about the use of Allium TPS, despite it being approved for clinical use for several years.

Regarding stent efficacy, the mean IPSS following stent insertion showed that all patients, who started with severe symptoms, had significant decrease in IPSS and were regarded as having mild symptoms (IPSS change of -18.7). We also provided urinary peak flow, which, despite its limitations, provides an objective measurement. We showed an increase of 10.5 mL/second in the peak urinary flow following Allium TPS insertion.

We are aware of our study limitations, which include a small number of patients and short-term follow-up. Most patients are still on follow-up and we will report a longer follow-up when available.

Conclusions

In this primary study of Allium TPS, we showed a new promising treatment option in patients with BPO who are unfit or unwilling to undergo classical prostatic surgery. Allium TPS is safe with minimal adverse effects and is effective, showing significant reduction in IPSS and increment in urinary flow. The stent can be easily inserted and easily removed if needed. A larger, randomized multicenter study should be conducted to prove our results.

Acknowledgment

The authors would like to thank Dr. Lisa Deutsch for statistical analysis.

Disclosure Statement

No competing financial interests exist.

References

1. Fabian KM. The intra-prostatic "partial catheter" (urological spiral) (author's transl). *Urologie A* 1980;19:236–238.
2. Corica AP, Larson BT, Sagaz A, Corica AG, Larson TR. A novel temporary prostatic stent for the relief of prostatic urethral obstruction. *BJU Int* 2004;93:346–348.
3. Guazzoni G, Montorsi F, Coulange C, et al. A modified prostatic UroLume Wallstent for healthy patients with symptomatic benign prostatic hyperplasia: A European Multicenter Study. *Urology* 1994;44:364–370.
4. Milroy E, Chapple CR. The UroLume stent in the management of benign prostatic hyperplasia. *J Urol* 1993;150(5 Pt 2):1630–1635.
5. Gravas S, Bach T, Bachmann A, et al. Guidelines on the Management of Non-Neurogenic Male Lower Urinary Tract Symptoms (LUTS), incl. Benign Prostatic Obstruction (BPO). 2015. Available at http://uroweb.org/wp-content/uploads/13-Non-Neurogenic-Male-LUTS_LR1.pdf (accessed June 12, 2015).
6. Gesenberg A, Sintermann R. Management of benign prostatic hyperplasia in high risk patients: Long-term experience with the Memotherm stent. *J Urol* 1998;160:72–76.
7. Kaplan SA, Chiou RK, Morton WJ, Katz PG. Long-term experience utilizing a new balloon expandable prostatic endoprosthesis: The Titan stent. North American Titan Stent Study Group. *Urology* 1995;45:234–240.
8. Perry MJA, Roodhouse AJ, Gidlow AB, Spicer TG, Ellis BW. Thermo-expandable intraprostatic stents in bladder outlet obstruction: An 8-year study. *BJU Int* 2002;90:216–223.
9. Van Dijk MM, Mochtar CA, Wijkstra H, Laguna MP, de la Rosette JJMCH. The bell-shaped nitinol prostatic stent in the treatment of lower urinary tract symptoms: Experience in 108 patients. *Eur Urol* 2006;49:353–359.
10. Kijvikai K, van Dijk M, Pes PL, Lertsithichai P, Wijkstra H, de la Rosette J. Clinical utility of "blind placement" prostatic stent in patients with benign prostatic obstruction: A prospective study. *Urology* 2006;68:1025–1030.
11. Armitage JN, Cathcart PJ, Rashidian A, De Nigris E, Emberton M, van der Meulen JHP. Epithelializing stent for benign prostatic hyperplasia: A systematic review of the literature. *J Urol* 2007;177:1619–1624.
12. Armitage JN, Rashidian A, Cathcart PJ, Emberton M, van der Meulen JHP. The thermo-expandable metallic stent for managing benign prostatic hyperplasia: A systematic review. *BJU Int* 2006;98:806–810.
13. Markovic BB, Markovic Z, Yachia D, Hadzi DJ. Nova generacija stentova uretre-Allium u terapiji simptomatskog uvećanja prostate različite etiologije. *Acta Chir Iugosl* 2007;54:71–76 [Article in Serbian].

Address correspondence to:
Zaher Bahouth, MD
Department of Urology
Faculty of Medicine
Bnai-Zion Medical Center
Technion Institute of Technology
Haifa 3339419
Israel

E-mail: zaher.bahouth@b-zion.org.il

Abbreviations Used

ASA = American Society of Anesthesiologists
 BPO = benign prostatic obstruction
 EAU = European Association of Urology
 IPSS = international prostate symptom score
 LS = least squares
 LUTS = low urinary tract symptoms
 PVR = postvoiding residual
 Qmax = maximal urinary flow
 TPS = triangular prostatic stent