



ENDOSCOPIC TREATMENT OF BILIARY COMPLICATIONS AFTER LIVER TRANSPLANTATION USING ALLIUM® METALLIC STENT

C. Haapamäki, M. Udd, J. Halttunen*, O. Lindström, H. Mäkisalo, L. Kylänpää
Department of Gastrointestinal Surgery, Helsinki University Central Hospital, Helsinki, Finland

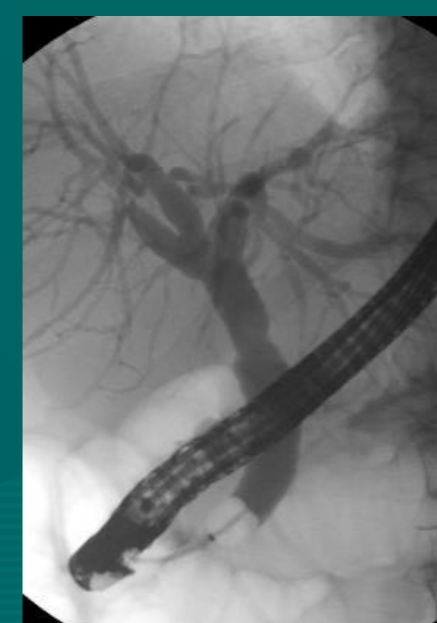
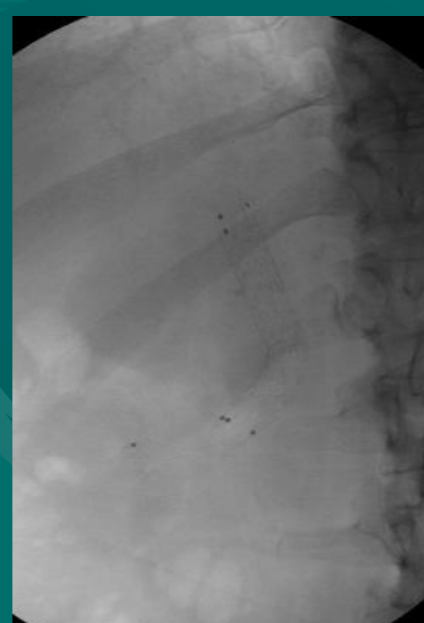
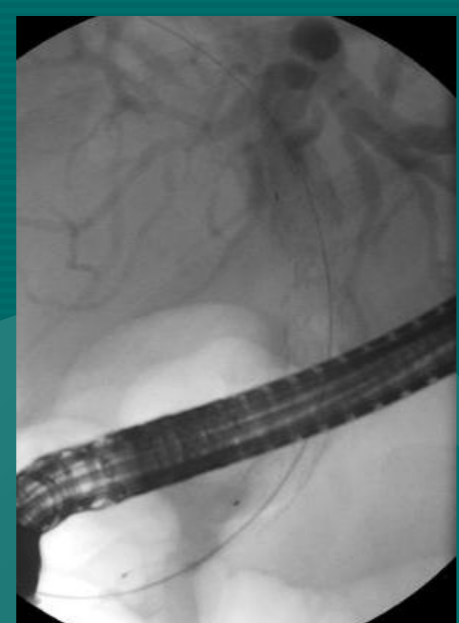
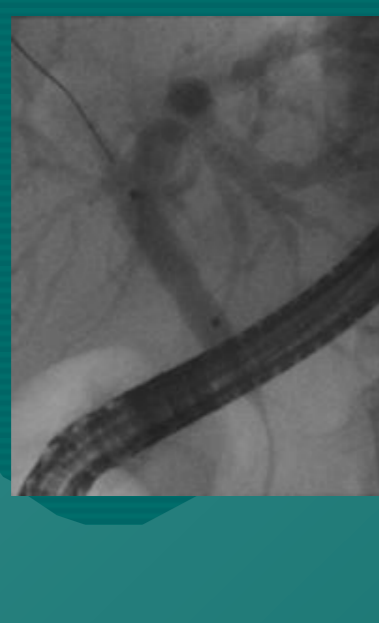
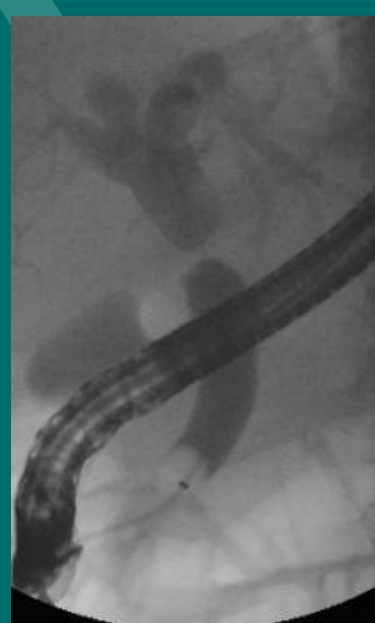
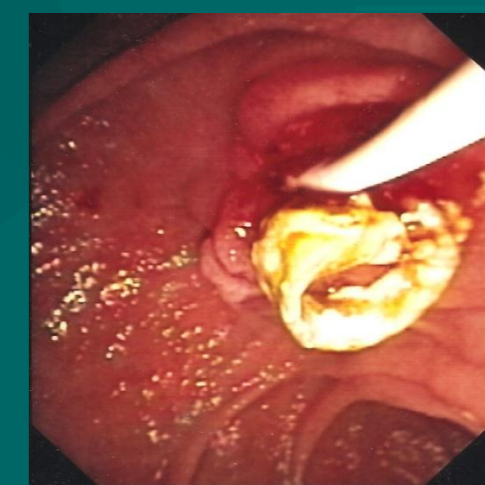
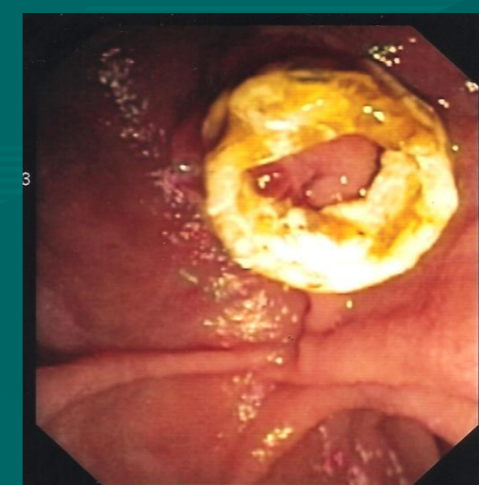OBJECTIVES: The incidence of biliary complications after liver transplantation (LT) has been 5-35%. In anastomotic stricture and biliary leakage after LT (duct-to-duct anastomosis), treatment has been dilation and application of plastic stents in ERCP (Endoscopic Retrograde Cholangiopancreatography) with a success rate of 70-80%. Results of removable fully covered, self-expandable metallic stents (cSEMS) in benign biliary strictures have been encouraging.

AIMS & METHODS: The aim of the study was to analyze therapy outcome of post-LT biliary stricture or leakage with Allium® cSEMS, which is placed entirely into the common bile duct. Single centre experience with 11 patients and 12 stenting entities during 2008-2010 is presented.

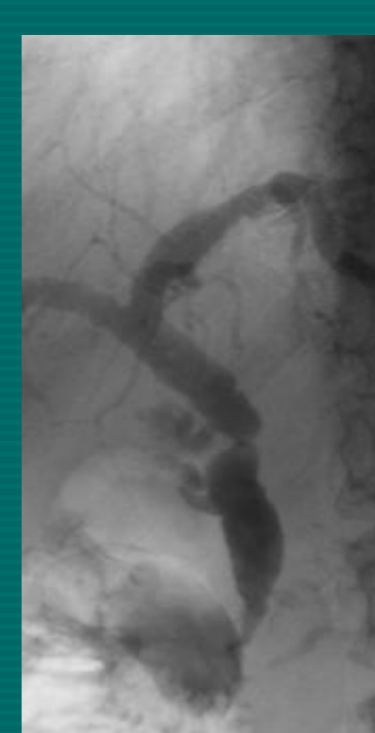
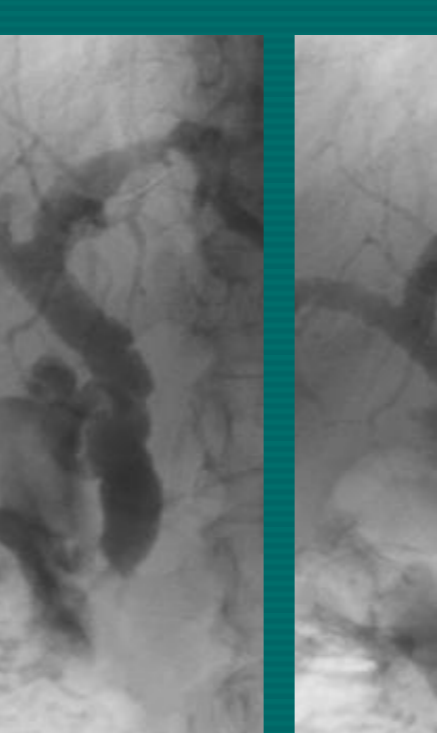
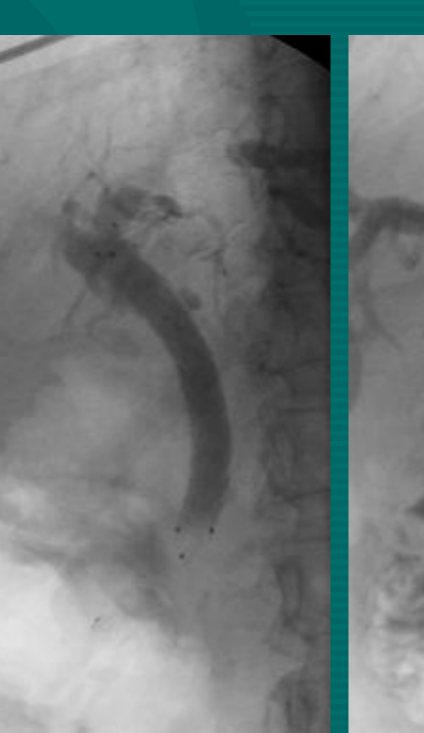
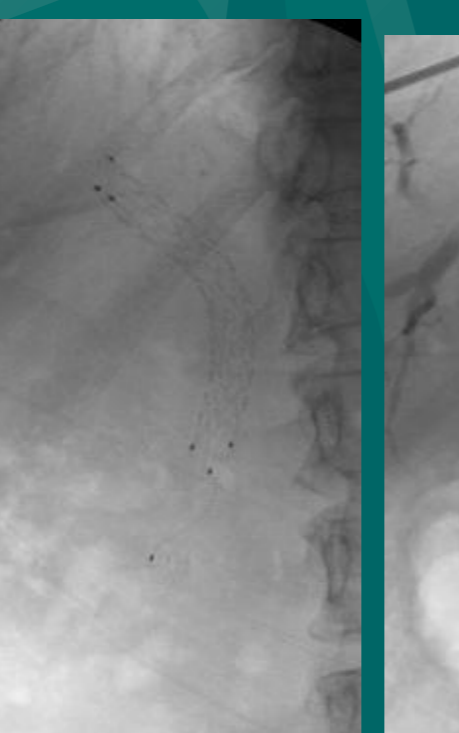
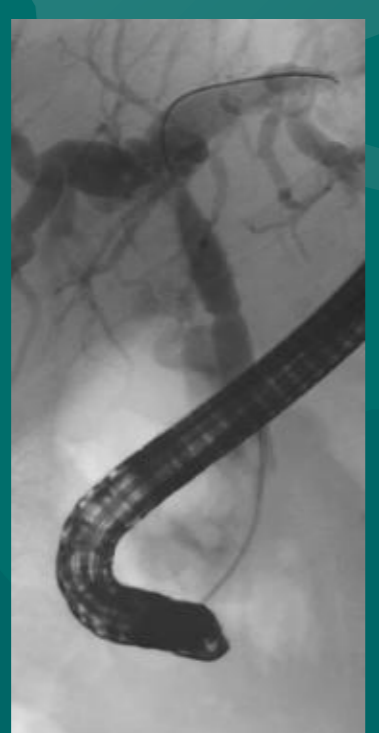
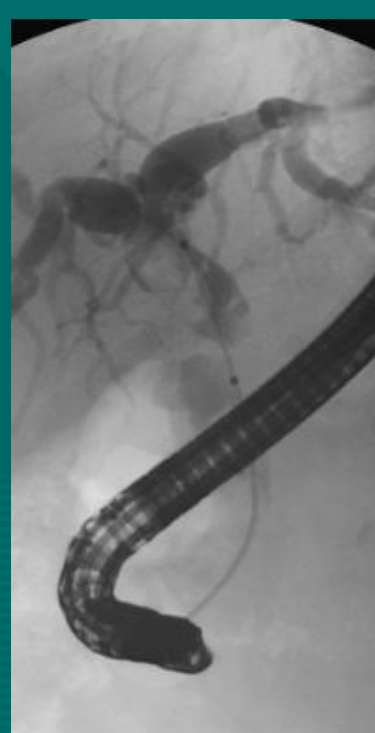
RESULTS: Eleven patients (3 male, median age 43, range 33-62) received a cadaveric liver graft between 1999 and 2009. Indication for stent placement was anastomotic stricture (n=10) and bile leakage (n=1). These patients had altogether 34 ERCPs connected to stentings. The mean number of procedures for each treatment entity was 2.8 (range 2-4). Duct stones or sludge were removed in 6 patients. cSEMS were placed in 18 ERCP procedures and prior dilation was performed in 12 of them. As the leak was patent after the 1st Allium® stent, another was put partly inside the existing one covering the leakage. In 5 treatment entities, one cSEMS was consecutively replaced with another as the stricture was not yet resolved. In one of them the stent migrated below the anastomose and was replaced by a custom made 4 cm long anchored cSEMS Microtec stent. One patient showed stricture recurrence in 1.5 month (mo) after resolution was established. It was re-treated successfully using Allium® cSEMS. The success rate was 92%, although in all 11 patients the anastomotic stricture was eventually cured with stenting. The mean stenting time was 6 mo (range 1-10). The mean follow-up time after stent removal was 9 mo (range 3-16). The patient with the leak had apparently ischaemic hilar and intrahepatic strictures as well. After leakage was resolved, the patient still suffered from episodes of cholangitis. The hilar strictures were treated with plastic stents without success, and re-LT was later performed. Complications were seen in 6 ERCPs (18%). Fever, interpreted as cholangitis, was seen three times. Although the stent anchor snapped in two occasions, there were no problems with the removability. There were no pancreatitis or deaths.



Allium® cSEMS stent with anchor, the anchor in duodenum with stent completely inside the common bile duct



A woman born in 1964
Liver Tx for Budd-Chiari syndrome in 2004, Re-Tx in 5/2005 for rejection
ERCP for biliary stricture on 19.11.2008 and placing an Allium stent, removal on 22.05.2009, follow-up on 14.06.2010 with normal liver values



A woman born in 1945,
Liver Tx for mushroom poisoning in 1999
ERCP's for biliary stricture on 14.02., 10.03., 09.06. and 10.12.2008. Control ERCP on 13.07.2009, follow-up on 13.08.2010 with normal liver status

CONCLUSION: According to this preliminary study, endoscopic treatment of LT related biliary complications using cSEMS (Allium®), seems to be both safe and efficient. It remains to be seen if these results are maintained as follow-up increases.

References:

- Tabibian JH, Asham EH, Han S, Saab S, Tong MJ, Goldstein L, et al. Endoscopic treatment of postorthotopic liver transplantation anastomotic biliary strictures with maximal stent therapy (with video). *Gastrointest Endosc.* 2010 Mar;71(3):505-12
- Vandenbroucke F, Plasse M, Dagenais M, Lapointe R, Letourneau R, Roy A. Treatment of post liver transplantation bile duct stricture with self-expandable metallic stent. *HPB (Oxford).* 2006;8(3):202-5.
- Wang AY, Ellen K, Berg CL, Schmitt TM, Kahaleh M. Fully covered self-expandable metallic stents in the management of complex biliary leaks: Preliminary data - a case series. *Endoscopy.* 2009 Sep;41(9):781-6.
- Traina M, Tarantino I, Barresi L, Volpes R, Gruttadauria S, Petridis I, et al. Efficacy and safety of fully covered self-expandable metallic stents in biliary complications after liver transplantation: A preliminary study. *Liver Transpl.* 2009 Nov;15(11):1493-8.
- Kahaleh M, Behm B, Clarke BW, Brock A, Shami VM, De La Rue SA, et al. Temporary placement of covered self-expandable metal stents in benign biliary strictures: A new paradigm? (with video). *Gastrointest Endosc.* 2008 Mar;67(3):446-54.