

# A New Self-Expanding, Large-Caliber Ureteral Stent: Results of a Multicenter Experience

Boaz Moskovitz, M.D.,\* Sarel Halachmi, M.D.,\* and Ofer Nativ, M.D.

## Abstract

**Background and Purpose:** Ureteral strictures (US) can be a recurrent chronic illness that leads to severe side effects and poor quality of life. Several options to treat US exist, including repeated dilations, stents, minimally invasive reconstructive surgeries, and urinary diversion or nephrectomy. Placement of an ureteral stent is a good minimally invasive option but has major limitations, such as stent migration, mucosal in-growth, encrustations, and stent obstruction. Our study aim was to evaluate the safety and the efficacy of a new self-expanding, large caliber ureteral stent (Allium®).

**Patients and Methods:** During 2005 to 2011, 49 stents were inserted in 49 renal units (40 patients) for a mean indwelling time of 17 months (range 1–63 mos).

**Results:** Migration was observed in seven (14.2%) patients, mandating stent removal. Only one stent was occluded. In eight renal units, the stents were removed as scheduled, and no reobstruction was detected during follow-up. Twenty-eight patients currently have a patent stent.

**Conclusions:** The Allium stent provides an attractive solution for long-term internal ureteral drainage. Its design allows good anchoring, prevents intraluminal ingrowth, and has the ability of rapid disintegration for extremely easy removal.

## Introduction

URETERAL STENTS HAVE BEEN used when the patency of the lumen has been compromised as a result of benign or malignant strictures, obstructing calculi, infiltrative processes, including malignancies, and also extrinsic compression. Currently, chronic ureteral stenosis is managed by a percutaneous nephrostomy tube or by a polymer or a metal Double J stent. All offer safe and efficient urinary drainage; however, they are related to many side effects, including tissue erosion, infection, and tube encrustation necessitating frequent replacement (every few months).<sup>1</sup>

Tissue ingrowth and massive encrustation are common problems that can cause difficulties or inability to remove the stent. Metal mesh stents have shown more promising results with a low rate of complications; however, they are not covered by medical insurance here.<sup>2</sup>

For the above mentioned reasons, we evaluate the long-term feasibility and effectiveness of a new self-expanding, large caliber ureteral stent (URS) (Allium®, Allium LTD, Caesarea, Israel), instead of repeated use of a Double J stent or a nephrostomy tube in patients with chronic ureteral stenosis.

## Patients and Methods

The Allium URS is a fully covered, self-expanding, large caliber metal stent especially designed for the ureter. The metal self-expanding component of the stent is made of a super-elastic nickel-titanium alloy (nitinol). The entire stent is covered with a new biocompatible, biostable polymer to make it a nonpermeable tube to prevent tissue ingrowth into the lumen and early encrustation. The Allium URS comes in two calibers (24F and 30F) and in two lengths (10 cm and 12 cm). It has a main body with high radial force with softer end segments. The main segment is connected with a single wire passing the ureterovesical junction (UVJ) to an intravesical anchor portion (Fig. 1). Longitudinally the URS is very flexible and has a strong enough radial force to keep the ureter lumen open by opposing the ureteral wall to allow intraluminal flow.

The Allium URS comes mounted on a 10F antegrade or retrograde insertion device. The stent also have a special unraveling feature to make its endoscopic removal easy, non-traumatic, and secure (Fig. 2). The URS does not shorten during or after its deployment, making its positioning accurate and stable. Because of its anchoring system, it is best used primarily as a segmental proximal and distal ureteral stent.

Department of Urology, Bnai Zion Medical Center, Rappaport Faculty of Medicine, Technion-Israel Institute of Technology, Haifa, Israel.  
\*Drs. Moskovitz and Halachmi contributed equally in the preparation of this manuscript.




FIG. 1. Allium ureteral stent structure; stent flexibility. UVJ = ureterovesical junction.




FIG. 2. (a-c) The Allium ureteral stent is designed for easy unraveling.

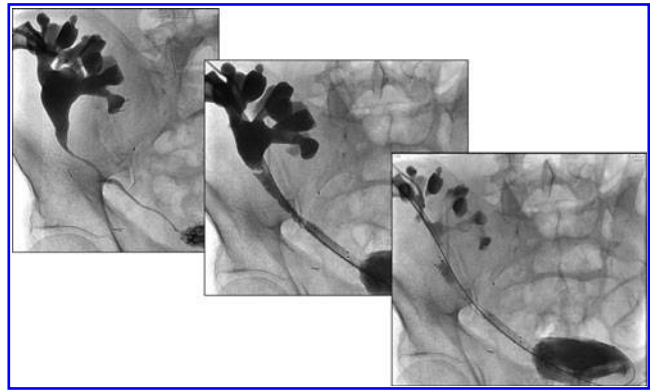


FIG. 3. Insertion of two consecutive Allium ureteral stents to a long ischemic ureteral stricture of a transplanted kidney.

Insertion of URS was performed under general or regional anesthesia. The ureters were contrasted antegradely via the nephrostomy tube or retrogradely by a ureteral catheter that replaced the Double J stent, with iodine injected under fluoroscopic control showing the site of narrowing.

In sequence, a guide wire was introduced and a ureteral balloon dilator passed over the wire to the site of pathology and inflated to 20 atm (1.72 MPa) according to the manufacturer's recommendations. After fluoroscopy confirmed disappearance or significant diminution of "waist," the stent was inserted into the strictured ureter (retrograde or antegrade) and its position fluoroscopically confirmed (Fig. 3).

In four different centers (in Israel, Italy, Serbia, and Spain) and after local Institutional Review Board approval, the Allium URS was inserted into 49 occluded ureters in 40 patients. Thirty-one patients had a nephrostomy tube and 9 patients had chronic Double J stent placement. From the 31 patients with a nephrostomy tube, in 20 patients the URS was inserted antegradely, in 11 combined (antegrade dilation/retrograde insertion); in the other 9 cases, the URS was inserted retrogradely.

#### Follow-up

For patients with underlying malignant obstruction, CT urography was used to assess renal function and oncologic status; for patients with nonmalignant obstruction, 6 weeks after stent insertion, diethylenetriaminepentaacetic acid (DTPA) renography was performed. If results of renography did not show obstruction, baseline ultrasonography was performed; then we used sonography for follow-up looking for changes in hydronephrosis.

#### Results

From March 2005 until October 2011, we enrolled 40 patients (49 ureteral strictures [US]) into the study. The clinical parameters of the patients who underwent Allium URS insertion and follow-up are shown in Table 1. Seventeen patients had US after surgery and radiation therapy for gynecological malignancies, 8 after endoscopic resection of bladder cancer; 5 strictures occurred at the ureteroenteric anastomosis after urinary diversion for muscle invasive bladder cancer, 5 strictures occurred after endoscopic treatment of ureteral stones, and 2 strictures occurred in a patient with

TABLE 1. PATIENT CHARACTERISTICS AND FOLLOW-UP

<i>Mechanism of stricture</i>	<i>No. patients</i>	<i>Ureteral units</i>	<i>Indwelling time (mos) (range)</i>	<i>Migration No.</i>	<i>Stent obstruction</i>	<i>Ureteral patency after ureteral stent removal (mos)</i>
Following surgery/radiation therapy for gynecologic malignancy	17	25	1–63	3 (at 3–6 months)	0%	1 patient (45) 3 patients (8–11)
Following surgical and topical treatment for bladder cancer	8	8	9–13	1 (at 3 months)	0%	1 patient (27) 2 patients (6–11)
Ureteroenteric anastomosis stricture after urinary diversion	5	5	15–17	1 (at 1 month)	0%	
Following endoscopic treatment of ureteral calculi	5	6	1–13	0	16%	1 patient (9)
Ureterocutaneostomy stricture	2	2	2	2 (at 2 months)	0%	
Renal transplant	3	3	12–15	0	100%	
Total	40	49	Av. 17 months	7 ( 14.2% )	98%	8

ureterocutaneous diversion performed for congenital anomalies that were later complicated and mandated diversion.

All stents were inserted successfully and positioned correctly in the 49 ureters. No significant adverse events related to the stent or to the procedure were recorded. During a mean follow-up time of 21 months (range 1–63 mos), only one of the stents was occluded after 11 months. In eight ureters, the stent was removed endoscopically after an average time of 11 months (range 9–12 mos). Stent migration (1–6 mos after insertion) occurred in seven (14.2%) ureters (five into the bladder, and two into the renal pelvis). After migration, the stents were endoscopically removed (except in one patient who refused any endoscopic treatment). In two patients with early migration, a new stent was reinserted successfully for an additional 10 and 12 months, respectively.

All eight patients in whom the URS was removed as scheduled are asymptomatic with a patent upper urinary tract after a follow-up time that ranged from 6 to 45 months. Currently, 28 patients have a patent stent and continue periodic follow-up. Thirteen patients died from their primary malignancy carrying a patent stent. In eight patients, the stent was removed at a scheduled time. All of them had immediate ultrasonography that showed no new hydronephrosis—four (with no malignant strictures) had nonobstructed DTPA renography 6 to 8 weeks after stent removal, and three patients who had malignant disease are still await CT urography for oncologic and urodynamic evaluation. Currently, all three are asymptomatic regarding urologic symptoms.

## Discussion

Independent of the etiology, prolonged obstruction or narrowing of the ureter can severely compromise the renal function of the involved kidney. Urinary drainage is necessary for pain relief, to reduce the risk of infection, and above all, to restore adequate renal function.

URS or percutaneous nephrostomy tubes have been used when the patency of the lumen has been compromised as a result of benign or malignant strictures, obstructing calculi, infiltrative processes, including malignancies, and also extrinsic compression. Both provide safe and efficient urinary drainage.<sup>2–5</sup>

URS are effective but carry various side effects including infection, bladder irritation, or bleeding and require frequent replacements every 3 to 6 months. In rare occasions, severe internal stent encrustation may prevent its endoscopic removal, mandating open surgery.<sup>1,5</sup>

A nephrostomy tube has a negative impact on patient quality of life. It is uncomfortable for the patient and, in addition, can be associated with infection, skin erosion, tube encrustation, obstruction, or accidental removal. In this situation, the patient undergoes frequent replacement with its inconvenience and costs.<sup>6</sup>

A stent is a device that is intended to keep a biologic passage open. It can vary in shape, length, and dimension, as well as in physical and biologic properties, and can be designed for permanent or temporary application. The stents may be fabricated from polymer, metal, biologic material, or combinations of these.<sup>7,8</sup>

Currently, chronic benign or malignant ureteral stenosis is managed by polymer or metal Double J stents. The biologic properties of stents refer to their interactions with tissue and body fluids. Therefore, the polymeric Double J stents have to be changed every 3 to 6 months to prevent the risk of occlusion, encrustation, infection, tissue erosion, and polymer disintegration.

The Resonance® metal coil stent that has a 6F caliber is device, Double J in shape, that is designed for long-term indwelling as well as for extreme extrinsic compression. Urine drainage is carried out by two mechanisms: Capillary-flow around the coiled external surface of the stent and also through the stent. Unfortunately, this stent is not included in the Ministry of Health national medical insurance coverage.

The new large-caliber, self-expanding Allium URS made of a super elastic nickel-titanium alloy ensures lumen patency by providing direct wall support. These stents have been fashioned to provide long-term wall support. The entire stent is covered with a new biocompatible polymer to make it a nonpermeable tube to prevent tissue ingrowth into the lumen and early encrustation, thus facilitating its removal even after a long indwelling period.

The stent also has a special unraveling feature to make its endoscopic removal, whenever needed, easy, nontraumatic, and secure.

Our study demonstrated that after proper insertion, the Allium URS provided initial luminal patency in 48 of 49 ureters (98%), proved by either CT urography or DTAP nuclear renography. Unfortunately, seven (14.2%) stents migrated, reducing the total success rate to 95%, mandating stent removal in six patients. One patient with cutaneous ureterostomy refused any intervention and remained with an indwelling Foley catheter that passes through the migrated stent. Three patients had removal and immediate reinsertion and three other patients had their stent removed after sufficient time; hence, they remain without a stent. In all three, no clinical symptoms of flank pain or urinary tract infection occurred; immediate ultrasonography did not reveal any new hydronephrosis. The DTPA scan showed no obstruction in two and one refused radiation imaging.

Fortunately no encrustations were documented, most probably because of the thin copolymer that covers the entire stent lumen, preventing intraluminal ingrowth and hyperplastic reaction, allowing the stenotic area to remain open, as long as the stent is in place.

Liatsikos and associates<sup>9</sup> evaluated the efficacy of the Resonance metallic stent in 18 patients with ureteral obstruction. Only 44% of the patients maintained patency after a mean follow-up of 7 months. Most failures occurred within a few weeks as a result of hyperplastic tissue reaction around the coils and gross calcification. Newer data provided by Benson and colleagues<sup>2</sup> showed better results with a metal stent. Out of 42 renal units with stent insertion, only three (7%) failures were documented. One stent located at the distal ureter was obstructed because of encrustation of the bladder anchoring portion. In this case, the patient who had bladder outlet obstruction with significant postvoid residual urine volume had his intraureteral portion of the stent patent and without encrustation.

Stent migration occurred only in 7 of the 49 (14.2%) procedures. In two patients with cutaneous ureterostomy, the stent migrated within the ureter toward the kidney. In one patient, the stent was easily removed and the other refused its removal. This patient's kidney is drained with an indwelling Foley catheter that passes easily through the migrated stent and is replaced every 12 weeks without difficulties. The remaining five patients with strictures in various sites of the middle third of the ureter had their stent removed without difficulties, and in two of them, a new stent was reinserted successfully. The anchoring mechanism seems to be less efficient in mid-US probably because its anchoring segment is also located in the ureter. This is different from ureteropelvic or UVJ strictures, where the anchoring segment is located in the renal pelvis and in the bladder, respectively.

Stent migration is a significant problem for both intraluminal and endoluminal stents. Motola and coworkers,<sup>10</sup> who described their experience with ureteral stents after endopyelotomy, reported a 14% migration and repositioning rate. Gibbons<sup>11</sup> initially addressed the problem of downward migration of soft silicone stents by adding barbs along its shaft, a stent design that bears his name. All currently available, completely internalized stents combat migration with the presence of a proximal and distal J or pigtail. Nevertheless, peristalsis may discharge a stent (especially one constructed from softer materials) from the ureter. One can also speculate that the prevalence of this complication will increase with the use of stents coated with

hydrophilic materials. Stent migration has been observed for metallic stents as well. Papdopoulos and colleagues<sup>12</sup> showed their experience with 13 Memokath metallic stents for the management of US and reported migration in 6 (43%) of the cases.

In our study, the Allium URS was successfully used in a wide variety of complex clinical situations, including in patients who had previous radiation therapy, after surgical ureteral injury, and even after renal transplant.

In two patients with strictures that were longer than the stent body length, two successive Allium URS were inserted at the same procedure, emphasizing the ability to provide a solution even in such cases.

Our results indicate that the use of Allium URS is feasible, safe, and effective for long periods without the need for secondary interventions to maintain ureteral patency (average 17 mos).

A more extensive experience is necessary with a larger number of patients and longer follow-up to confirm the efficacy of these new stents.

## Conclusion

Allium URS are an excellent solution for temporarily long-term internal ureteral drainage. Insertion of the stent is simple and its positioning is under fluoroscopy; the removal can be performed under local anesthesia as an outpatient procedure. Being covered by a thin copolymer, intraluminal ingrowth was prevented allowing prolonged indwelling time and simple removal. The stent is best used for proximal and distal strictures. Mid-US can also be managed with the stent; however, most of the migration cases occurred in this setting.

This minimally invasive treatment alternative is more efficient than current endoscopic treatments, is safe, tolerated by the patient, and more cost effective.

## Acknowledgments

The authors thank: Dr. Gianpaolo Carrafiello, Department of Radiology, University of Insubria, Varese, Italy; Dr. Zeljko Markovic, Dr. Vesna Stojanovic, Dr. Biljana Markovic, Institute of Radiology, and Dr. Jovan Hadzi Djokic, Institute of Urology and Nephrology, Clinical Center of Serbia, Belgrade, Serbia; Dr. Ernesto M. Santos, Vascular and Interventional Radiology Section, Hospital Clinico San Carlos, Madrid, Spain, for helping in data collection.

## Disclosure Statement

No competing financial interests exist.

## References

1. Infection and encrustations on stents. In: Yachia D, ed. *Stenting the Urinary System*. 1st ed. Oxford, UK: Isis Medical Media Ltd, 1998, pp 71–98.
2. Benson AD, Taylor ER, Schwartz BF. Metal ureteral stent for benign and malignant ureteral obstruction. *J Urol* 2011;185: 2217–2222.
3. Praz V, Chollet Y, Jichlinski P. [Indications and methods of invasive minimal urinary derivations in oncology.] (*Fre*) *Rev Med Suisse* 2007;3:2788–2792.

4. Kanou T, Fujiyama C, Nishimura K, et al. Management of extrinsic malignant ureteral obstruction with urinary diversion. *Int J Urol* 2007;14:689–692.
5. Duvdevani M, Chew BH, Denstedt JD. Minimizing symptoms in patients with ureteric stents. *Curr Opin Urol* 2006;16:77–82.
6. Stables DP. Percutaneous nephrostomy: Techniques, indications, and results. *Urol Clin North Am* 1982;9:15–29.
7. Mardis HK, Kroeger RM, Morton JJ, Donovan JM. Comparative evaluation of materials used for internal ureteral stents. *J Endourol* 1993;7:105–115.
8. Stent materials. In: Yachia D, ed. *Stenting the Urinary System*. 1st ed. Oxford, UK: Isis Medical Media Ltd, 1998, pp 31–69.
9. Liatsikos E, Kallidonis P, Kyriazis I, et al. Ureteral obstruction: Is the full metallic double-pigtail stent the way to go? *Eur Urol* 2010;57:480–486.
10. Motola JA, Badlani GH, Smith AD. Results of 212 consecutive endopyelotomies: An 8-year follow-up. *J Urol* 1993;149:453–456.
11. Gibbons RP. Gibbons ureteral stents. *Urol Clin North Am* 1982;9:85–88.
12. Papadopoulos GI, Middela S, Srirangam SJ, et al. Use of Memokath 051 metallic stent in the management of ureteral strictures: A single-center experience. *Urol Int* 2010;84:286–291.

Address correspondence to:

*Sarel Halachmi, M.D.*

*Department of Urology*

*Bnai Zion Medical Center*

*47 Golomb Street*

*Haifa 31048*

*Israel*

*E-mail: Sarel.halachmi@b-zion.org.il*

#### **Abbreviations Used**

CT = computed tomography

DTPA = diethylenetriaminepentaacetic acid

URS = ureteral stent

US = ureteral strictures

UVJ = ureterovesical junction