



New management of upper urinary tract obstruction by using Allium® stents

J. Alefelder, F. Salem, T. Noorzai
Eichsfeldklinikum gGmbH Reifenstein, Department of Urology

Introduction:

Chronic ureteral stenosis are usually treated by frequently exchanged DJ-stents or by nephrostomies, which also have to be exchanged regularly. This study was performed to evaluate the effectiveness of a long lasting stenting by a new self-expanding, large caliber ureteral stent (Allium-URS®).

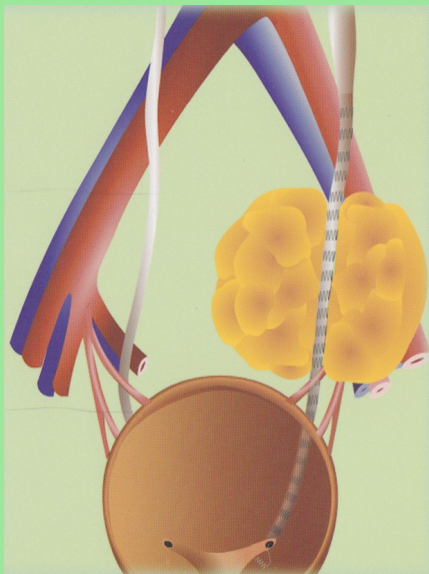


Figure 2: Allium-URS® in ureter

Material and Methods:

The Allium-URS® is a new developed, self-expanding metal- stent made out of a super elastic nickel-titanium alloy (Nitinol), which is completely covered by a biocompatible copolymer to make it a non-permeable tube. This prevents tissue ingrowths and early encrustation. Due to its high flexibility it is possible to implant the stent even in tortuous passages. The Allium-URS® is available in two calibers (24 and 30 Fr.) and two different lengths (10 and 12 cm). The stent has a main-body with high radial force (to keep the ureter lumen open) and two softer segments for reduction of the friction between the stent and ureteral-wall. This prevents the induction of reactive tissue proliferation, which is a problem seen in other metal stents. The distal edge of the stent is attached by a single wire passing the ureteral-vesical-junction to an intravesical anchor (fig. 2)
The Allium-URS® was implanted into 23 obstructed ureters in 19 patients. All patients were previously on chronic DJ-stenting or nephrostomies. 21 stents were inserted retrogradely and 2 antegradely. All strictures were dilated by a single-use ureteral-dilatation set (Rüsch, Wiener Model®) previous to implantation. Most strictures were dilated to 14 French. Although the Allium-URS® is designed for stenosis in the lower ureter we used it successfully in four cases with a sub- pelvic stenosis(fig. 3).

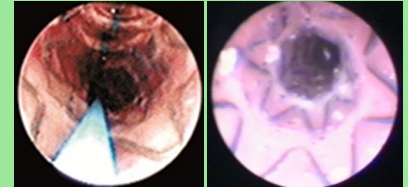


Figure 1: Stent expanded and inserted

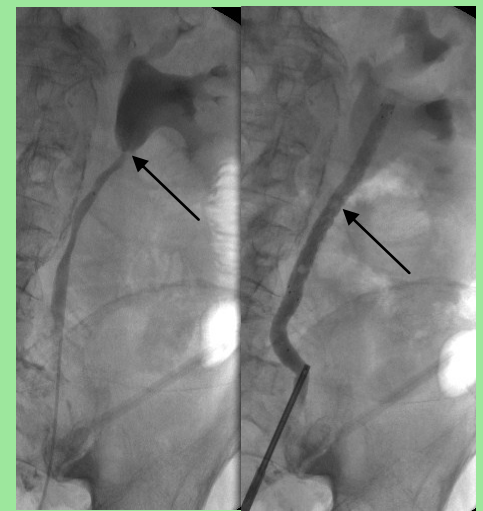


Figure 3: Allium-URS® by sub pelvic stenosis

Results:

During the mean follow-up of 10 months none of the stents occluded. In one of the patients the drainage of the kidney was insufficient due to the length of the ureteral obstruction. In this case the 12 cm stent was too short to keep the entire stricture open. In two patients we saw a migration of the stent into the bladder; in one patient the stent migrated into the renal pelvis. In this patient the Allium stent has to be removed by nephroscopy. Apart from the migrated stents no further complications occurred. All other patients were asymptomatic after the implantation.

Discussion:

Although the Allium-URS® is designed for strictures in the lower ureter it nevertheless can be used successfully in stenosis in the upper ureter too (fig. 3). The limitation of its use is only the length of the stricture. If the stent is too short a placement is not possible or even when it is possible, it doesn't drain the kidney. Therefore URS-stents in various different sizes are desirable. Dislocations of the stent occur early after implantation. We did not see any late migration.

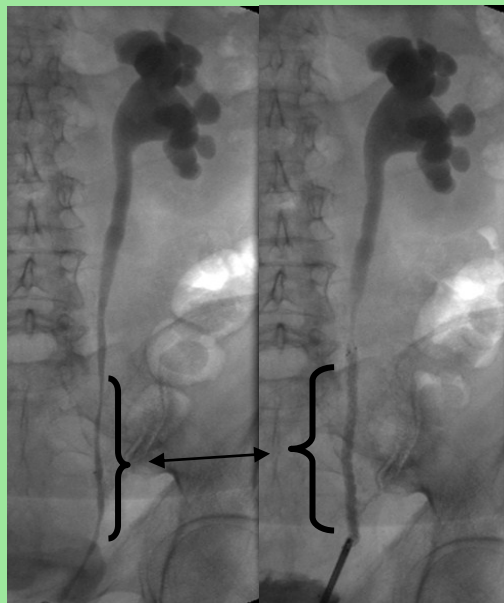


Figure 4: Retrograd ureteropyelography before and after Allium URS® implantation by distal ureteral stenosis following wertheim operation

The main difference between the Allium URS and the conventional double- J stent is that the large caliber Allium URS allows intraluminal flow during all its indwelling time . URS caliber= 8 or 10 mm, Lumen caliber= 7 or 9 mm
Double- J stent caliber= 2,3 mm, Lumen caliber= 1,4 mm

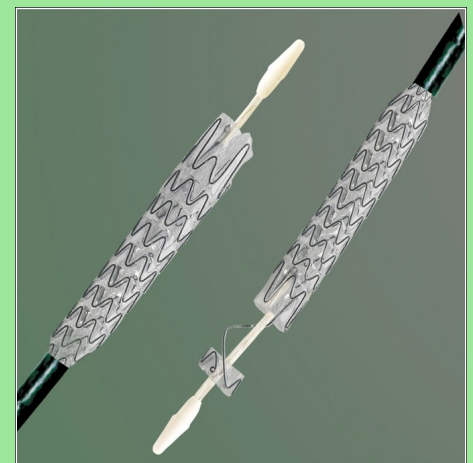


Figure 5: Allium URS® after expanding

Conclusion:

In our series we were able to show that the use of Allium®-stents in the management of chronic ureteral stenosis is feasible, effective. No secondary intervention to maintain patency is needed in up to 18 months. The Allium-URS® is an appropriate way to manage chronic ureteral obstruction.